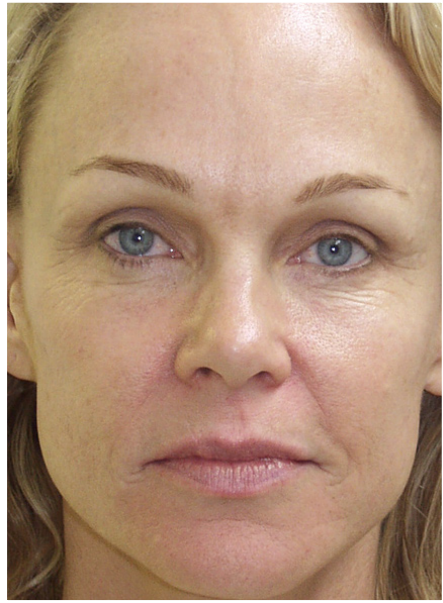

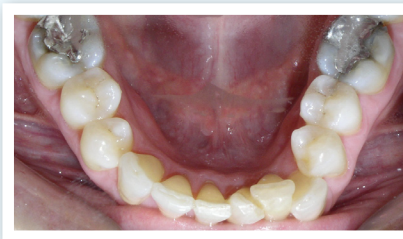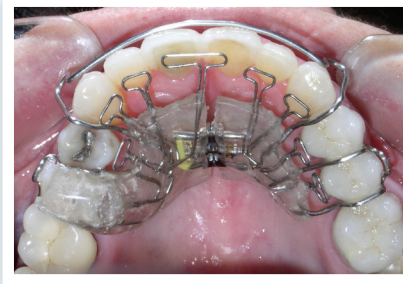CASE STUDY : This study shows a patient over a four year period using the NuSmile Face Lift Appliance, the Homeoblock™, and then followed up by placement of dermal fillers.

NuSmile Face Lift

non-surgical



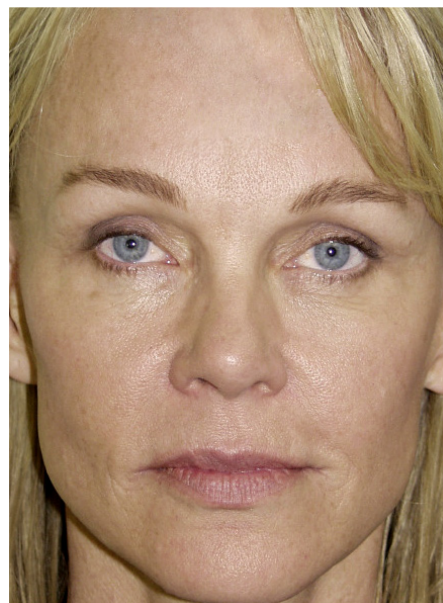Patient before treatment with the NuSmile Face Lift Appliance.
August 2003



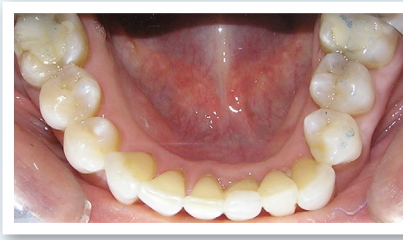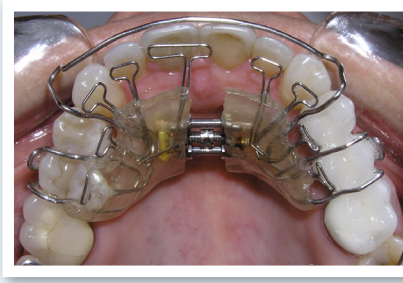
The patient is in her early fifties. She shows lines and wrinkles, a deep nasolabial depression and sagging buccal fat pad.

Intra-orally, her lower teeth are crowded.

The NuSmile FaceLift appliance will help correct all of these issues.

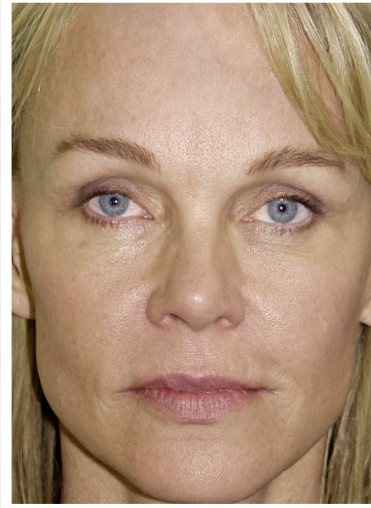
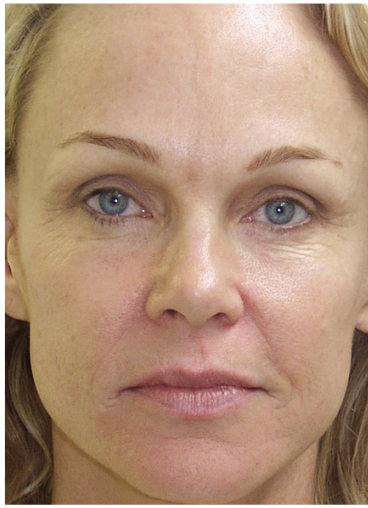
Patient after sixteen months of treatment with the NuSmile Face Lift Appliance.
December 2004



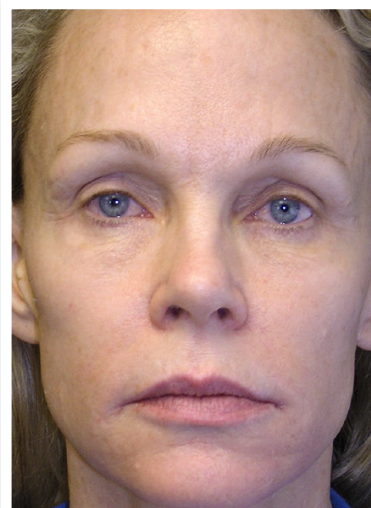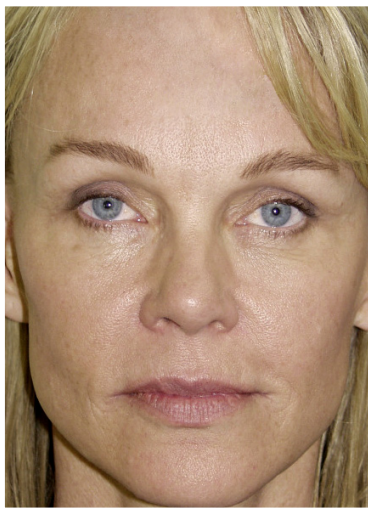Sixteen months after using the NuSmile Face Lift Appliance.

- More level eyes
- More prominent cheek- bones
- Reduced nasolabial depression




**Before and After
Treatment with NuSmile
Face Lift Appliance**

Sixteen months later we have more level eyes, more prominent cheekbones and reduced nasolabial depression.



**Before and After
Treatment with Dermal
Fillers**

Patient four years later includes placement of dermal fillers. More level eyes, more prominent cheekbones, fuller lips, fewer lines and wrinkles, stronger jaws. And she is four years older!



**Before and After
Morphometric**

Removing the surface texture shows the reduction of the sagging buccal fat pad, pre treatment photo, resulting in a non-surgical face lift.